

Abdomen X-Ray (AXR)

Collimation is ideally from diaphragms to lower border of the symphysis pubis and the lateral skin margins.

LMP of child-bearing age female patients should be checked.

1. Acute abdomen

1.1. PA chest

To exclude basal pneumonia as a cause of upper abdominal pain

To show any small amount of free air beneath the diaphragms

To demonstrate the general condition of the heart and lung fields (for GA)

1.2. Supine AXR

Outlines of abdominal viscera

Demonstrates any soft tissue mass, calcifications

Distended gas-filled bowel loops in the case of obstruction

Signs of inflammation of the right psoas muscle or the flank stripe

Technique:

- Patient lying supine on the couch
- Check both ASIS are equidistant
- Align the mid-line of the patient to the mid-line of the beam
- Center to the mid-line at the level of the lower corstal margin
- Expose in arrested respiration

1.3. Erect AXR

Any free gas under diaphragms

Fluid level in the peritoneal cavity

Abnormal gaseous distention of the GI tract

Technique:

- Patient stands facing the erect bucky with the abdomen in contact with the bucky
- Both arms encircle the bucky for immobilization
- Align the midline of the patient to the midline of the beam
- Center to the midline at the level of the lower corstal margin
- Expose in arrested respiration

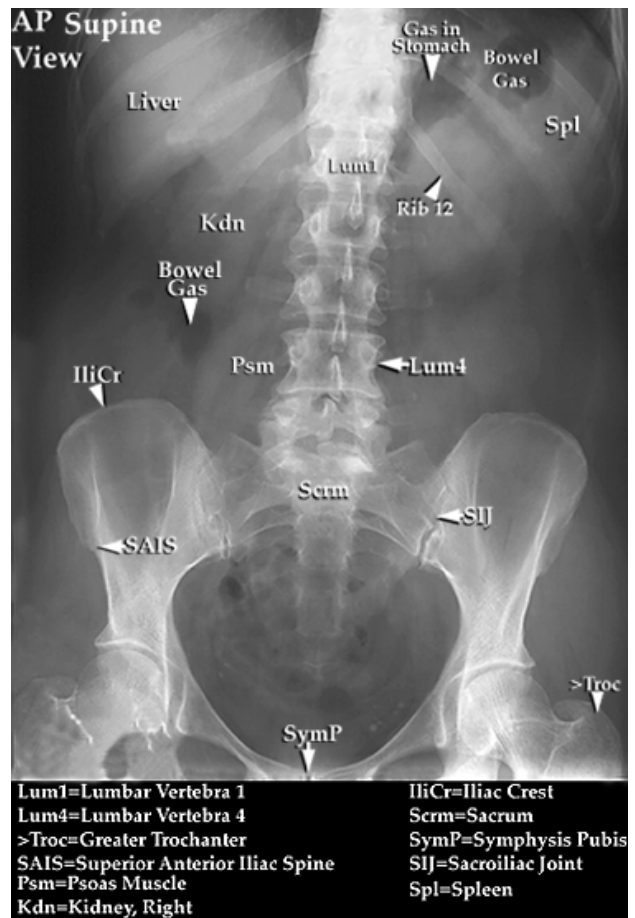
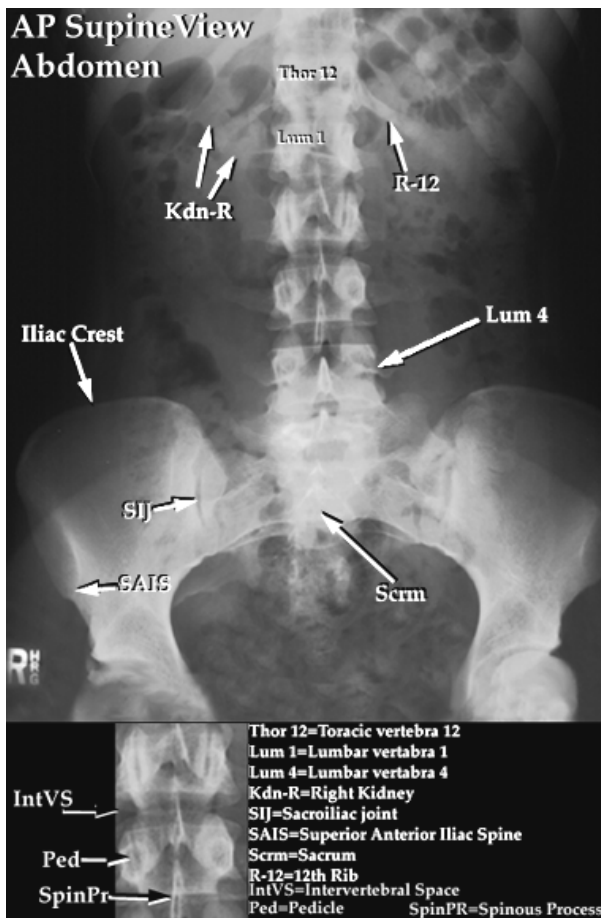
Modification:

If patient cannot stand, AP sitting AXR can also achieve the purpose.

Same for erect AXR, but the patient is sitting facing the tube with the back in contact with the bucky.

If the patient cannot be positioned in erect position, LEFT decubitus AXR can achieve the purpose.

With the patient lies on left side facing or backing the tube, both arms are raised over the head. Centering point is same as supine AXR.



2. Urinary system

2.1 KUB

Same as AXR, but center to the level of iliac crest

2.2 Bladder view

If the patient is tall, single film may not cover the whole urinary tract.

The first film is AXR. The second film is bladder view.

Technique:

- Same positioning as AXR
- Center in the midline at the level of 2.5cm below the ASISs with 15° caudally tube tilting

2.3 Lateral AXR

Differentiate calculi

Technique:

- The patient is turned to the affected side (usually RIGHT side)
- The arms are raised over head and legs are flexed in hips and knees
- Adjust the patient's MSP is parallel to the cassette
- Align the midline of the patient to the midline of the beam
- Center to the midline of the body at the level of the lower corstal margin
- Expose in arrested respiration

2.1 Obliques

Determine intra-renal and extra-renal calculi

Technique:

The patient is turned 10-15° towards the affected side

Center to the sound auxillary line at the level of the kidneys

Expose in arrested respiration

3. Biliary system

3.1 AXR

3.2 LAO

- The patient lies prone with head turned to the right, right arm raised over head and right knee flexed slightly
- Left arm is by the patient's side
- Adjust the body to 20° towards the right side.
- Center to the lower corstal margin midway between the spinous processes and the right lateral skin margin
- Low kV is preferred

4. Exposure parameter

To produce optimal contrast of an area of low inherent contrast, it is necessary to use a low kV technique. This demonstrates maximum soft tissue differentiation (i.e. it should produce a “softer” result showing grey tones rather than black and white contrast). The density and contrast of the radiographs should be such that the psoas muscle, kidneys, lower border of the liver and flank strips are clearly shown.

Exposure time should be short to reduce the movement blur. Small renal and biliary calculi will be easily obscured if small degrees of movement are present.

5. Pathology

5.1 Gas shadows

If there is an apparently largely air filled bowel which contains plenty of air up to a certain part of the bowel, this may indicate some form of obstruction.

If the colon seems to be overextended, this may indicate constipation.

If free air in an area within the peritoneal cavity but where there is not part of the alimentary canal (e.g. beneath diaphragms), this may indicate an ulcer.

5.2 Psoas muscles

The outer margins form strip, like shadows on either side of the spine, extending from L1 down to the pelvis.

If they are altered or obliterated, it may indicate inflammation (acute appendicitis), perforated duodenal ulcer, haemorrhage of the kidney or neoplasm.

5.3 Flank stripes

This is the fatty layer which lies next to the peritoneum in the abdominal wall. It is not visible when it lies parallel to film but it is at the sides where it turns downwards to the patient’s back and the X-ray beam catches it tangentially.

Haemorrhage, for example, in the supine film will collect in the flanks and a wide area will separate the fat from the colon, or, the flank will be blown out.

5.4 Calcified lesions

Not all biliary calculi will be opaque.

Other areas of calcification can occur in the walls of arteries, lymph nodes, ureters, uterus, etc..